

# 1 Modular Guide Series

## Worm Control in Dogs and Cats

There is a wide range of helminths, including nematodes, cestodes and trematodes, that can infect dogs and cats in Europe.

Major groups by location in the host are:

### Intestinal worms

- Ascarids (Roundworms)
- Whipworms
- Tapeworms
- Hookworms

### Non-intestinal worms

- Heartworms
- Subcutaneous worms
- Lungworms

The following series of modular guides for veterinary practitioners gives an overview of the most important worm species and suggests control measures in order to prevent animal and/or human infection.

### Key companion animal parasites

**1.1** Dog and cat roundworms (*Toxocara* spp.)

**1.2** Heartworm (*Dirofilaria immitis*)

**1.3** Subcutaneous worms (*Dirofilaria repens*)

**1.4** French heartworm (*Angiostrongylus vasorum*)


**1.5** Whipworms (*Trichuris vulpis*)

**1.6** Dog and fox tapeworms (*Echinococcus* spp.)

**1.7** Flea tapeworm (*Dipylidium caninum*)

**1.8** Taeniid tapeworms (*Taenia* spp.)

**1.9** Hookworms (*Ancylostoma* and *Uncinaria* spp.)



## Diagnosis of helminth infections

Patent infections of most of the worms mentioned can be identified by faecal examination. There are exceptions. Blood samples can be examined for microfilariae in the case of *D. immitis* and *D. repens*, for antigens for *D. immitis* and *A. vasorum* and antibodies (for *D. immitis* in cats only).

Faecal examination for worm eggs or larvae should be carried out with at least 3–5 g faeces. Eggs of ascarids, hookworms, whipworms and *Taenia*-type eggs are easily recognisable. For the detection of lungworm larvae, the Baermann method should be used.

Since dogs and cats may ingest or eat faeces, care should be taken to identify and eliminate false positive results caused by coprophagia.

<sup>1</sup> See [www.esccap.org](http://www.esccap.org) for links to therapy tables by country or region.

## Preventive measures

- Parasite infections should be controlled through endoparasite and ectoparasite management, tailored anthelmintic treatment at appropriate intervals and faecal examinations<sup>1</sup>.
- All common worms, with some exceptions such as *Dirofilaria* species, are transmitted by the passage of eggs or larvae in faeces, therefore hygiene measures, especially cleaning up pet faeces regularly, will reduce environmental contamination with infective parasite stages.
- Feeding commercial diets or cooked food helps prevent raw meat-transmitted parasite infections. Dogs and cats should not be allowed access to rodents, carcasses, placentae or aborted foetuses of livestock. They should also be provided with clean water.
- When recommending a parasite management programme, veterinarians should consider the animal's age, reproductive status, health status, history including travel, nutrition and environment.

## Preventing zoonotic infection

Pet owners should be informed about the potential health risks of parasitic infection, not only to their pets but also to family members, friends and neighbours. Regular deworming or joining “pet health-check programmes” should be introduced to the general public by veterinary practitioners, veterinary nurses and other animal health professionals. Responsible dog and cat ownership, together with good personal hygiene, can reduce public health concerns.

- Carefully remove dog and cat faeces from yards and pens and dispose of responsibly.
- Practice good personal hygiene e.g. wash hands, keep fingernails short, rinse fruit and vegetables and wear gloves when working in soil.
- Dogs and cats should be dewormed regularly, at least four times a year or following veterinary advice based on a risk assessment.
- Always feed commercial dry or canned diets or cooked food, NOT raw meat.
- Keep children away from contaminated areas. Reduce the risk of sandpit contamination by using covers.



Adapted from the original ESCCAP Guideline 01 Second Edition – September 2010 © ESCCAP 2010. All rights reserved.

ISBN 978-1-907259-41-8

ESCCAP guidelines are made possible by sponsorship from ALL the major leading pharmaceutical companies.

### Ruby Sponsors:



### Sapphire Sponsors:

ESCCAP Secretariat  
Malvern Hills Science Park  
Geraldine Road, Malvern  
WR14 3SZ  
United Kingdom

Tel: +44 (0) 1684 585135  
[www.esccap.org](http://www.esccap.org)

# 1 Modular Guide Series

## 1.1a: Dog roundworm (*Toxocara canis*)

*Toxocara canis* is a large, intestinal nematode that can cause disease in dogs and foxes. It is also zoonotic.

*Toxocara canis* is a large worm with adults measuring as much as 15 cm in length. Puppies can be heavily infected by *T. canis* worms in utero or via their mother's milk and this may cause serious illness in the pups before diagnosis of patent infection is possible by faecal examination.

### Distribution

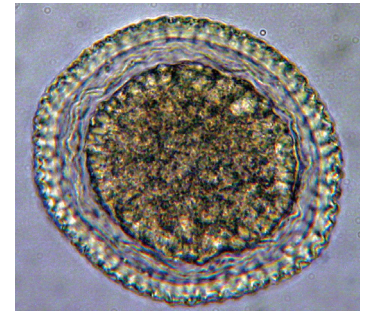
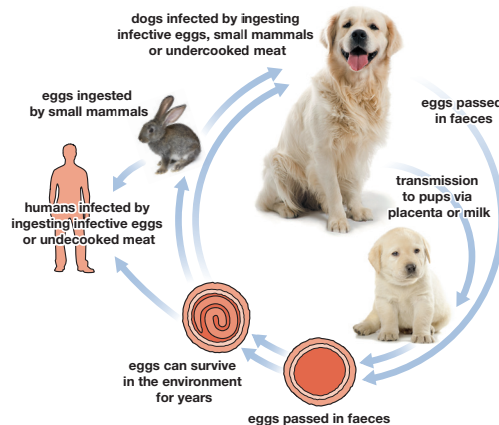
*Toxocara canis* is ubiquitous in dog and fox populations throughout the world. Prevalence of patent infections is higher in puppies and lower in adolescent and adult dogs. However, there is no immunity at any age and adult dogs may show patent infections.

### Life Cycle

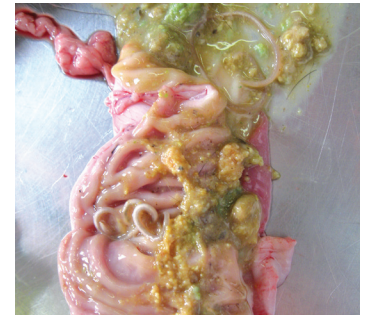Adult worms inhabit the small intestine where they lay eggs that are then passed in the faeces. The eggs can become infective after several weeks and these can survive in the environment for years. Dogs become infected when they ingest infective eggs. The eggs hatch in the intestine releasing larvae that penetrate the intestinal wall and undergo a hepato-tracheal migration, with the life cycle completed when larvae are coughed

up and swallowed, returning to the small intestine to complete their migration.

Somatic migration can occur in older canines and non-canid hosts that can then act as paratenic hosts. In puppies, infection can occur by the passage of larvae across the placenta from about the 42nd day of pregnancy and later through the milk.



*Toxocara canis* egg



Adult worms live in the small intestine of infected dogs

Dogs can also become infected when they ingest infective eggs from the environment, eat undercooked meat or prey on an infected paratenic host (e.g. rodent). Infection of humans can occur as a result of accidentally ingesting infective eggs or undercooked meat containing larvae.

## Clinical Signs

Puppies carrying a heavy burden may appear cachexic with a distended abdomen. They may also show pulmonary signs, have loose faeces and may develop an intussusception. Older dogs are extremely unlikely to show clinical signs. Occasionally a worm may be passed in faeces or seen in vomit.

## Diagnosis

*Toxocara* eggs are easily recognisable. Diagnosis is based on identifying eggs in faeces by using the flotation method with 3–5 g faeces (fresh or fixed). *Toxocara cati* eggs can be present in a sample as a result of coprophagia.

## Treatment

**Puppies** should be treated with appropriate anthelmintics, normally starting when they are 14 days old, continuing at fortnightly intervals until two weeks after weaning and then monthly treatments to six months of age.

**Nursing bitches** should be treated concurrently with the first treatment of their offspring since they may have patent infections.

Infection can occur in old dogs but is extremely unlikely to be associated with clinical signs; consequently it is difficult to tell whether a dog is infected unless regular faecal examinations are conducted. In **adult dogs** it has been shown that an increase in treatment frequency effectively reduces occurrence and monthly deworming can largely prevent patent infections as it takes into account the biology of the parasites.

After ingestion of larvae via predation of paratenic hosts or infective eggs from the environment, the pre-patent period for *Toxocara* spp. is a little over four weeks.

Monthly treatment with a suitable anthelmintic will minimise the risk of patent infections and can be recommended in high-risk scenarios such as the pet living in a family with small children and with access to gardens or parks. Deworming at least four times per year is the general recommendation<sup>1</sup>. Where an owner chooses not to use anthelmintic therapy regularly or local legislation requires diagnosis or risk assessment prior to treatment, then monthly or three-monthly faecal examination may be an alternative.

## Control

Dogs should not be fed undercooked or raw meat and care should be taken to prevent them hunting. Faeces should be collected and disposed of regularly and areas used by dogs should be kept clean. An appropriate anthelmintic should be given at suitable intervals.

<sup>1</sup> See [www.esccap.org](http://www.esccap.org) for links to therapy tables by country or region.



Adapted from the original ESCCAP Guideline 01 Second Edition – September 2010 © ESCCAP 2010. All rights reserved.

ISBN 978-1-907259-41-8

ESCCAP guidelines are made possible by sponsorship from ALL the major leading pharmaceutical companies.

### Ruby Sponsors:



### Sapphire Sponsors:

ESCCAP Secretariat  
Malvern Hills Science Park  
Geraldine Road, Malvern  
WR14 3SZ  
United Kingdom

Tel: +44 (0) 1684 585135  
[www.esccap.org](http://www.esccap.org)

# 1 Modular Guide Series

## 1.1b: Cat roundworm (*Toxocara cati*)

*Toxocara cati* is a large, intestinal nematode that can cause disease in cats. It is also zoonotic.

*Toxocara cati* is a large worm with adults measuring as much as 10 cm in length. Kittens can be heavily infected by *T. cati* worms via the milk and these may cause serious illness before diagnosis is possible by faecal examination.

### Distribution

*Toxocara cati* is ubiquitous in cat populations throughout the world. Prevalence of patent infections is highest in kittens, lower in adolescent cats and lowest in adult cats. However, there is no absolute prevention of infection in adult cats.

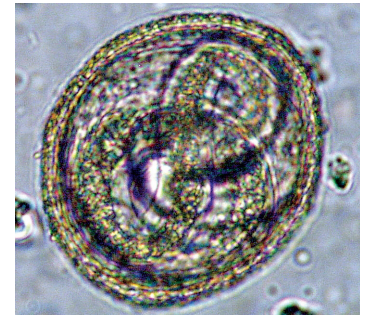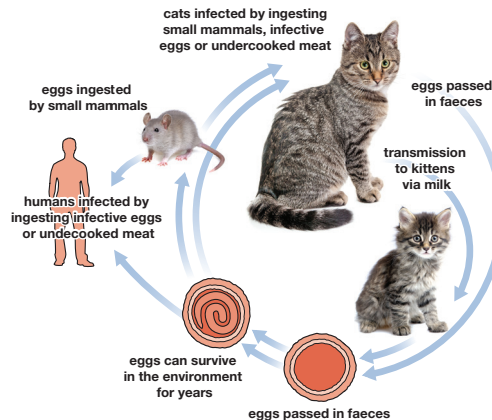
### Life Cycle

Adult worms inhabit the small intestine where they lay eggs that are then passed in the faeces. The eggs can become infective after several weeks. Cats are infected when they ingest infective eggs from the environment.

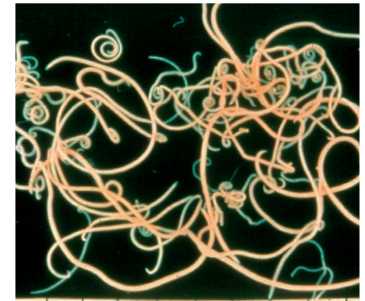
The eggs hatch in the intestine releasing larvae that penetrate the intestinal wall and undergo a hepato-tracheal migration, with the life cycle completed when the larvae are coughed up and swallowed, returning to

the small intestine to complete their migration. Kittens can be infected through the milk. Somatic migration occurs in older felines and non-feline hosts that can then act as paratenic hosts.

Cats can also become infected when they eat undercooked meat or an infected paratenic host as prey. Infection of humans can occur as a result of accidentally eating infective eggs or undercooked meat containing larvae.



*Toxocara cati* infective egg



Adult worms live in the small intestine of infected cats

## Clinical Signs

Infected kittens may show respiratory signs associated with a heavy burden of migrating larvae. Kittens carrying a heavy burden may appear cachexic with a distended abdomen. Older cats are extremely unlikely to show clinical signs. Occasionally a worm may be passed in faeces or seen in vomit.

## Diagnosis

Diagnosis is based on identifying eggs in faeces by using the flotation method with 3–5 g faeces (fresh or fixed). *Toxocara* eggs are easily recognisable.

## Treatment

Because prenatal infection does not occur in **kittens**, fortnightly treatment can begin at three weeks of age and be repeated fortnightly until two weeks after weaning, then monthly for six months.

**Nursing queens** should be treated concurrently with the first treatment of their offspring, since they may have patent infections.

Infection can occur in **adult cats**, and is extremely unlikely to be associated with clinical signs; thus it is difficult to tell whether a cat is infected unless regular faecal examinations are conducted. It has been shown that an increase in treatment frequency effectively reduces the occurrence of positive animals; studies have shown that worming four times a year does not necessarily eliminate patent infections, while a monthly deworming can largely prevent patent infections as it takes into account the biology of the parasites.

The pre-patent period for *Toxocara* spp. after ingestion of larvae via predation of paratenic hosts (rodents) or infective eggs from the environment is a little over four weeks. Monthly treatment will therefore minimise the risk of patent infections and can be recommended in high-risk scenarios such as the pet living in a family with small children with access to gardens or parks.

Current information suggests annual or twice yearly treatments do not have a significant impact on preventing patent infection within a population, so a treatment frequency of at least four times per year is a general recommendation<sup>1</sup>.

Where an owner chooses not to use anthelmintic therapy regularly or local legislation requires diagnosis or risk assessment prior to treatment, then monthly or three-monthly faecal examination may be an alternative.

## Control

Cats should not be fed undercooked or raw meat. Preventing predation, collecting and disposing of faeces and good hygiene practices (e.g. between litters of kittens) are all important preventive measures that should be combined with appropriate anthelmintic treatments at suitable intervals for a given cat or cats.

<sup>1</sup> See [www.esccap.org](http://www.esccap.org) for links to therapy tables by country or region.



Adapted from the original ESCCAP Guideline 01 Second Edition – September 2010 © ESCCAP 2010. All rights reserved.

ISBN 978-1-907259-41-8

ESCCAP guidelines are made possible by sponsorship from ALL the major leading pharmaceutical companies.

### Ruby Sponsors:



### Sapphire Sponsors:

ESCCAP Secretariat  
Malvern Hills Science Park  
Geraldine Road, Malvern  
WR14 3SZ  
United Kingdom

Tel: +44 (0) 1684 585135  
[www.esccap.org](http://www.esccap.org)

# 1 Modular Guide Series

## 1.2: Heartworm (*Dirofilaria immitis*)

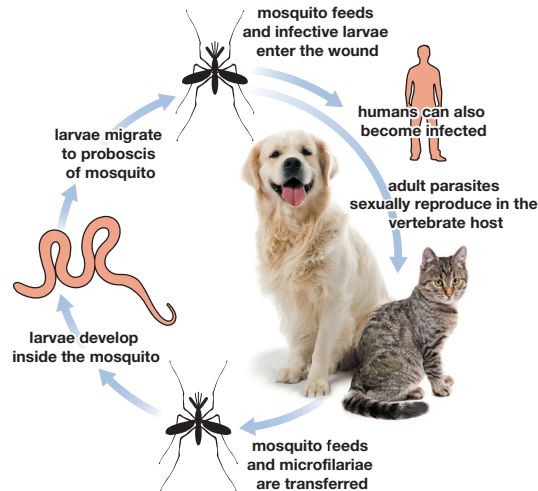
*Dirofilaria immitis* is a filarial worm that resides in pulmonary arteries of dogs and cats. Also known as heartworm, it is transmitted by intermediate mosquito hosts. It is zoonotic but human infection is rare.

### Distribution

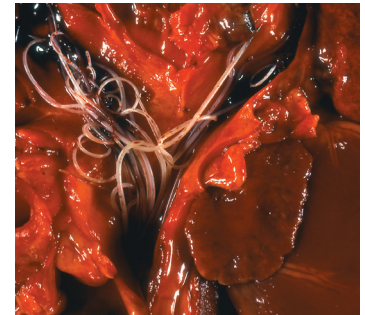*Dirofilaria immitis* is endemic/hyperendemic in many countries of southern, central and eastern Europe. The prevalence in cats is generally only a tenth of that in dogs.

### Life Cycle

*Dirofilaria immitis* has an indirect life cycle. Dogs and cats are the final hosts. The adult parasite sexually reproduces in its vertebrate host, and the offspring (called microfilariae) are transferred to the intermediate host, which is usually a mosquito. The larvae develop inside the mosquito and when the mosquito feeds, the infective larvae enter the canine or feline host through the wound. The parasite migrates within the connective tissue for approximately 3–4 months and then enters the host's bloodstream and arrives in the pulmonary arteries. Mature females release offspring 6–7 months post infection, which become available to blood-sucking mosquitoes.



Heartworms are transmitted by different types of mosquitoes

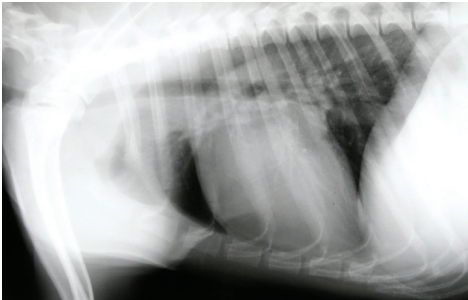


Adult worms live in the pulmonary arteries

## Clinical Signs

Infection with *D. immitis* may cause severe and potentially fatal disease in dogs and cats. Low worm burdens can be asymptomatic. Increasing worm burdens can cause clinical signs such as loss of condition, weakness, dyspnoea and chronic cough.

If untreated, the disease can progress to right-side heart failure and death. In cats, the disease is asymptomatic but may cause sudden death.



Heartworm infection causes pulmonary disease

## Diagnosis

Diagnosis of *D. immitis* is by blood tests to detect microfilariae and by serology to detect circulating antigens or antibodies.

## Treatment

The organic arsenical compound melarsomine dihydrochloride (2.5 mg/kg bodyweight) is the only effective drug available for use against adult heartworm infections. The recommended protocol is one deep intramuscular injection followed by two doses at an interval of 24 hours 50–60 days later<sup>1</sup>.

## Control

Control of heartworm in dogs and cats relies upon the use of preventive treatments to kill the young heartworm stages prior to migration to the pulmonary arteries. Monthly administration of topical or oral macrocyclic lactones throughout the transmission season, usually April to November, is effective. A slow-release formulation is available that lasts for six months<sup>2</sup>.

<sup>1</sup> See [www.esccap.org](http://www.esccap.org) for links to therapy tables by country or region.

<sup>2</sup> For more information see: ESCCAP Guideline 05: Control of Vector-Borne Diseases in Dogs and Cats.



Adapted from the original ESCCAP Guideline 01 Second Edition – September 2010 © ESCCAP 2010. All rights reserved.

ISBN 978-1-907259-41-8

ESCCAP guidelines are made possible by sponsorship from ALL the major leading pharmaceutical companies.

### Ruby Sponsors:



### Sapphire Sponsors:

ESCCAP Secretariat  
Malvern Hills Science Park  
Geraldine Road, Malvern  
WR14 3SZ  
United Kingdom

Tel: +44 (0) 1684 585135  
[www.esccap.org](http://www.esccap.org)

# 1 Modular Guide Series

## 1.3: Subcutaneous worms (*Dirofilaria repens*)

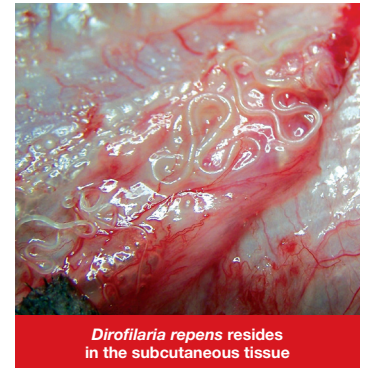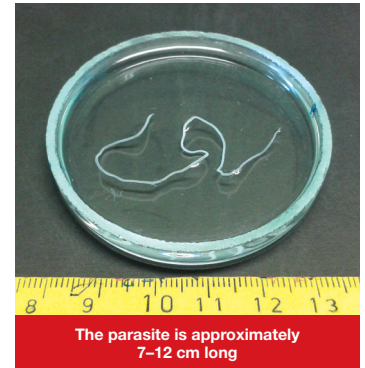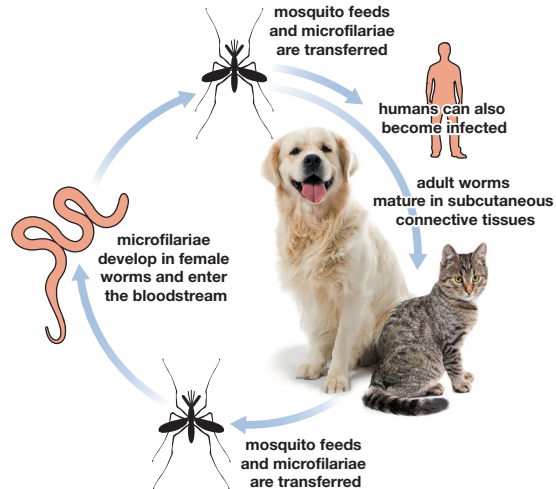
*Dirofilaria repens* is a subcutaneous filarial worm found in dogs and cats. It is transmitted via intermediate mosquito hosts. Humans can also become infected.

### Distribution

Areas where *D. repens* is endemic overlap with endemic *D. immitis* areas in many regions of Europe. *D. repens* is the main species occurring in areas such as northern France and Hungary and is the most important *Dirofilaria* species responsible for zoonotic infections in Europe. There have been recent reports of autochthonous infection in Germany, the Netherlands, Poland, Austria and Portugal. Autochthonous infections are contracted in the country where they are reported.

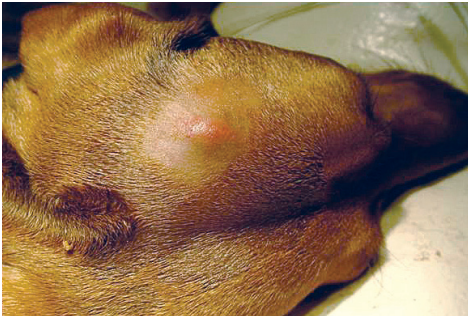### Life Cycle

The microfilariae develop in the uterus of female worms and are excreted into the bloodstream where they become available to the vectors that are blood-sucking mosquitoes. Further development occurs in the vector and transmission to the final host is via the vector's saliva during feeding. The adult worm then matures in the subcutaneous connective tissue.



## Clinical Signs

*Dirofilaria repens* is the species most frequently associated with subcutaneous filariasis of dogs and cats. Most infections are asymptomatic but in some cases, subcutaneous, non-inflammatory nodules containing adult parasites or microfilariae can be observed. Most infected dogs do not show clinical signs for years. In cases of heavy infection, severe dermatitis can be observed.



The worm may cause skin nodules and swelling

## Diagnosis

In dogs, blood tests can demonstrate the presence of microfilariae and reference should be made to ESCCAP Guideline 05<sup>1</sup> for a range of diagnostic options that may be appropriate. In cats, detection of microfilariae in the blood is unlikely to be successful as the density of the microfilariae in the circulation is very low.

## Treatment

No effective adulticide therapy is known for *D. repens*. Because of the zoonotic potential, microfilaraemic dogs should be treated monthly for a year with products able to kill microfilariae. Subcutaneous filariasis can be safely and effectively prevented in both dogs and cats by chemoprophylactic treatments. Monthly treatment with macrocyclic lactones (oral or spot-on formulations) is effective in preventing subcutaneous infection in dogs<sup>2,3</sup>.

## Control

In Europe *D. repens* is the most important agent responsible for human filarial infection so control in dogs and cats is essential.

Before and after travelling, dogs and cats should be examined for infection by *D. repens* microfilariae. When microfilariae are present in a blood sample, dogs and cats should not travel to non-endemic areas without prior microfilaricidal treatment.

Treatment using an appropriate prophylactic will give protection before entry into an endemic area.

For more information see:

- <sup>1</sup> ESCCAP Guideline 05: Control of Vector-Borne Diseases in Dogs and Cats.
- <sup>2</sup> ESCCAP Guideline 01: Worm Control in Dogs and Cats
- <sup>3</sup> See [www.esccap.org](http://www.esccap.org) for links to therapy tables by country or region.



Adapted from the original ESCCAP Guideline 01 Second Edition – September 2010 © ESCCAP 2010. All rights reserved.

ISBN 978-1-907259-41-8

ESCCAP guidelines are made possible by sponsorship from ALL the major leading pharmaceutical companies.

### Ruby Sponsors:



ESCCAP Secretariat  
Malvern Hills Science Park  
Geraldine Road, Malvern  
WR14 3SZ  
United Kingdom

Tel: +44 (0) 1684 585135  
[www.esccap.org](http://www.esccap.org)

# 1 Modular Guide Series

## 1.4: French heartworm (*Angiostrongylus vasorum*)

*Angiostrongylus vasorum* (French heartworm) is a nematode that resides as the adult stage in the pulmonary artery and right ventricle in dogs, foxes and some other carnivores (cats are not affected).

### Distribution

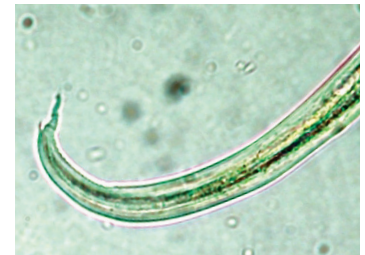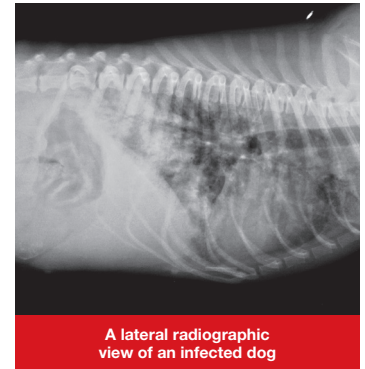
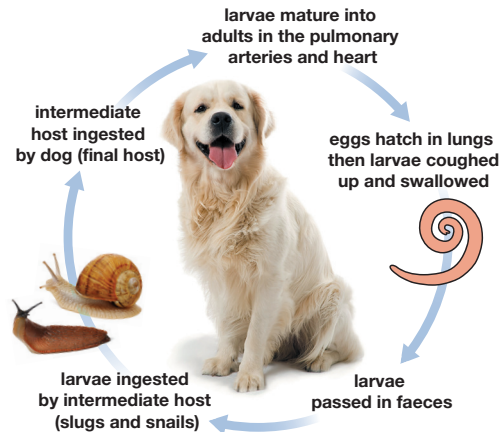
*Angiostrongylus vasorum* is prevalent in various European countries including the UK, Ireland, Portugal, Spain, France, Switzerland, the Netherlands, Belgium, Denmark, Germany, Italy, Hungary, Slovakia, Poland and Sweden.

Reservoir hosts include foxes and distribution in dogs may mirror that seen in foxes to some extent.

### Life Cycle

Slugs and snails serve as intermediate hosts. Dogs may also become infected by ingesting frogs which act as paratenic hosts. Following ingestion, larvae develop and migrate to the right ventricle and pulmonary artery. Female worms begin laying eggs from 38–60 days after infection. Eggs hatch rapidly and larvae penetrate the alveoli and are then coughed up and passed in faeces as first stage larvae.

Once an infection is established, patency may be very long; up to five years.



*A. vasorum* larvae measure approximately 345 µm and are characterised by a wavy tail with a dorsal notch<sup>A</sup>

<sup>A</sup> Photo courtesy Rolf Nijse, ESCCAP Benelux.

## Clinical Signs

**Early or light infection** No clinical signs

**Significant infection** Heavy productive cough  
Dyspnoea  
Anaemia  
Depression  
Anorexia  
Signs of coagulopathy

**Severe infection** Right-sided heart failure  
Sudden death

**Chronic infection** Verminous pneumonia leading to anorexia, weight loss, emaciation and pulmonary hypertension.

**Ectopic infection** Occasionally, larvae and rarely adult stages of *A. vasorum* are located in ectopic locations such as the brain, bladder, kidney or the anterior chamber of the eye. Clinical signs relating to invasion of these organs can occur.

## Diagnosis

Live larvae can be detected from 4 g of fresh faeces using the Baermann method. Faeces are sampled on three consecutive days due to large daily variation in larval excretion. Alternatively, microscopic detection of larvae in bronchial lavage material can be used. A commercial serological test for detection of the circulating antigen is also available.

## Treatment

Anthelmintic therapy includes the use of adequate macrocyclic lactone-based anthelmintics or repeated daily administration of benzimidazole-based anthelmintics (five days

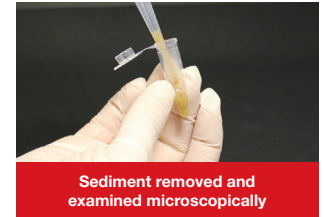
to several weeks)<sup>1</sup>. Supportive treatment, with antibiotic and glucocorticoid-based products and fluid substitution therapy, may be needed in severe clinical cases and the animal should be rested during the treatment period (at least 2–3 days).

## Control

The prophylactic use of adequate macrocyclic lactone-based products has been shown to be effective.

When possible dogs should be prevented from ingesting snails or slugs.

<sup>1</sup> See [www.esccap.org](http://www.esccap.org) for links to therapy tables by country or region.



Adapted from the original ESCCAP Guideline 01 Second Edition – September 2010 © ESCCAP 2010. All rights reserved.

ISBN 978-1-907259-41-8

ESCCAP guidelines are made possible by sponsorship from ALL the major leading pharmaceutical companies.

Ruby Sponsors:



Sapphire Sponsors:

ESCCAP Secretariat  
Malvern Hills Science Park  
Geraldine Road, Malvern  
WR14 3SZ  
United Kingdom

Tel: +44 (0) 1684 585135  
[www.esccap.org](http://www.esccap.org)

# 1 Modular Guide Series

## 1.5: Whipworms (*Trichuris vulpis*)

*Trichuris vulpis* (whipworm) is an intestinal nematode that can cause disease in dogs.

### Distribution

Infection with *Trichuris vulpis* occurs throughout Europe but is most likely to occur in central and southern areas of Europe where temperatures are most suitable for the environmental development of eggs (no development occurs below 4°C).

### Life Cycle

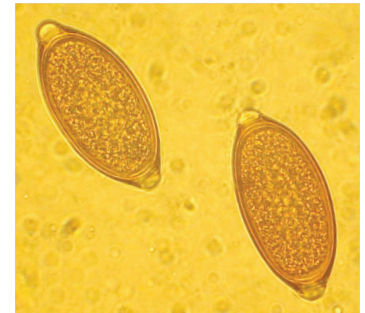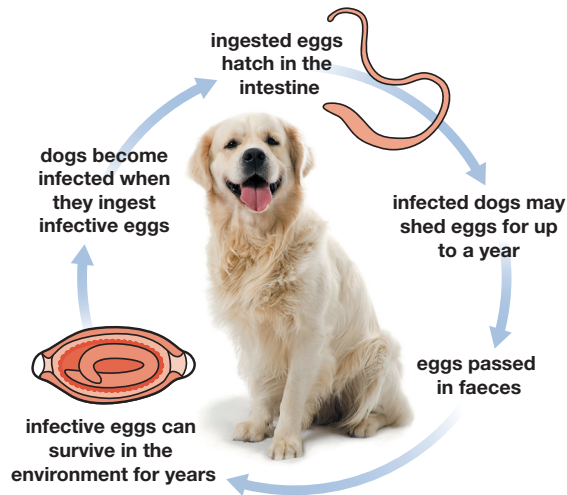
Eggs are passed in the faeces of infected dogs. The infective stage (L1) develops within the egg in 1–2 months. These infective stages can survive in the environment for years. Dogs become infected when they ingest infective eggs. The pre-patent period is 2–3 months and infected dogs may continue to shed eggs for up to a year.

### Clinical Signs


Heavy infection will result in diarrhoeic, bloody, mucoid faeces accompanied by weight loss. Ultimately, the animal will no longer be able to compensate and will become acutely ill. Metabolic disturbances including anaemia and hyponatraemia may also occur.

### Diagnosis

Infection can be diagnosed by finding characteristic “lemon-shaped” eggs on examination of 3–5 g of faecal samples using a suitable flotation technique.



*Trichuris vulpis* eggs<sup>B</sup>



*Trichuris vulpis* worm

<sup>B</sup> Photo courtesy Jakub Gawor, ESCCAP Poland.

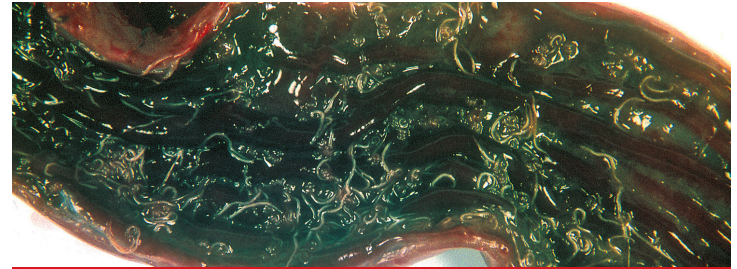
## Treatment

Most modern anthelmintics are effective against *T. vulpis*. To be effective, repeated deworming is often required<sup>1</sup>.

## Control

Clinical cases tend to occur in certain localised geographic areas or in specific premises such as kennels. Considerable and persistent contamination of the environment is common so control can be difficult as dogs can easily become re-infected if they remain in the same environment.

Where possible, dogs should be removed from contaminated areas. Since the eggs are difficult to eliminate from the environment, it may be necessary to consider resurfacing kennel flooring (e.g. by paving or laying concrete) to facilitate thorough cleaning. Rotavating and reseedling may also help to eliminate contamination.



A heavy infection of *Trichuris vulpis* in the large intestine of a dog



Increased risk of heavy infection in kennels with earth or straw runs



This kennel can be easily cleaned which reduces the risk of infection

<sup>1</sup> See [www.esccap.org](http://www.esccap.org) for links to therapy tables by country or region.



Adapted from the original ESCCAP Guideline 01 Second Edition – September 2010 © ESCCAP 2010. All rights reserved.

ISBN 978-1-907259-41-8

ESCCAP guidelines are made possible by sponsorship from ALL the major leading pharmaceutical companies.

### Ruby Sponsors:



### Sapphire Sponsors:



ESCCAP Secretariat  
Malvern Hills Science Park  
Geraldine Road, Malvern  
WR14 3SZ  
United Kingdom

Tel: +44 (0) 1684 585135  
[www.esccap.org](http://www.esccap.org)

# 1 Modular Guide Series

## 1.6a: Dog tapeworm (*Echinococcus granulosus*)

*Echinococcus granulosus* is a small cestode that inhabits the small intestine of dogs and some other canids, excluding foxes.

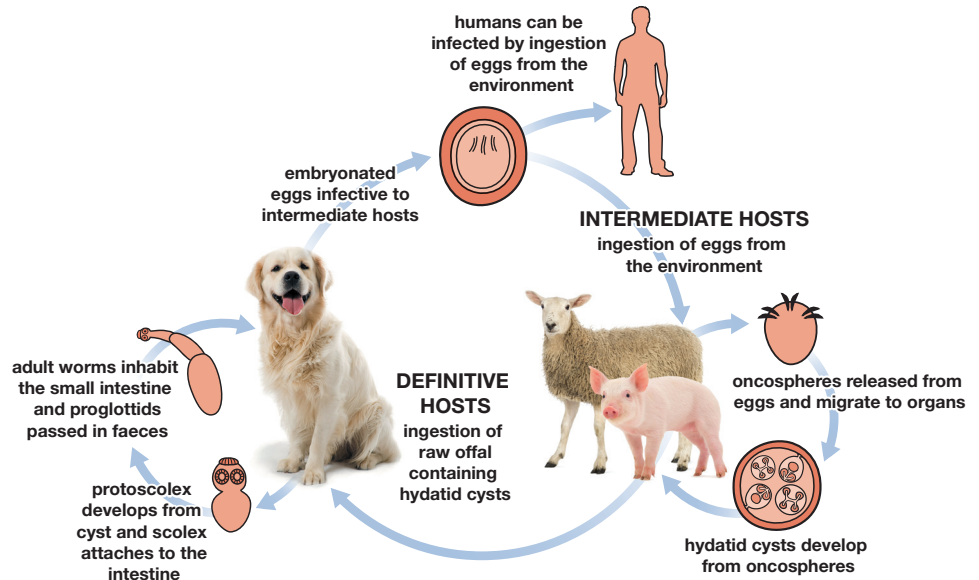
It is the cause of cystic echinococcosis in humans, due to infection with eggs passed in the faeces of infected canids.

### Distribution

*Echinococcus granulosus* in sheep and pigs and associated species, (*Echinococcus equinus* in horses and *Echinococcus ortleppi* in cattle), are endemic in discrete areas of Europe.

### Life Cycle

Adult worms inhabit the small intestine of canids with the terminal proglottid breaking off once it matures. This is passed in the faeces and contains eggs that are immediately infective to the appropriate intermediate host. Within the intermediate host, the immature tapeworm leaves the intestine, normally coming to rest in the liver and lung where it develops into a cyst containing many immature tapeworms. Final hosts become infected when they ingest the cysts within intermediate hosts.



## Clinical Signs

Infected dogs are extremely unlikely to show clinical signs. The segments are too small for them to be evident in faeces.

## Diagnosis

Specific diagnosis of *Echinococcus* infections in definitive hosts is difficult as the taeniid eggs cannot be differentiated morphologically and are passed intermittently. Coproantigen tests are not available commercially and Polymerase Chain Reaction tests (PCRs) for species and/or genotype identification are only performed in specialised laboratories.

Therefore, in *Echinococcus* endemic areas taeniid infections based on egg detection should be considered as a potential *Echinococcus* infection.

<sup>1</sup> See [www.esccap.org](http://www.esccap.org) for links to therapy tables by country or region.

## Treatment

Where animals are infected with *Echinococcus* species, treatment with an anthelmintic containing praziquantel or epsiprantel is advisable, carried out under veterinary supervision<sup>1</sup>.

Dogs should be shampooed to remove any parasite eggs adhering to the coat.

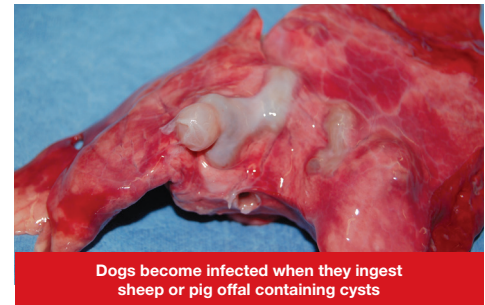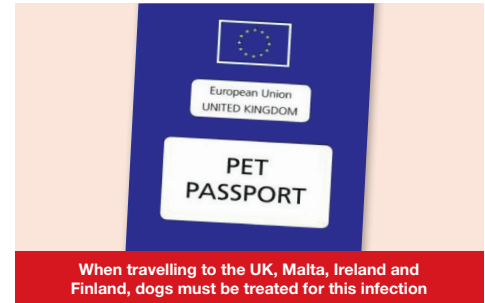The faeces of treated dogs should be properly disposed of.

Personnel involved should use suitable protective clothing including protective gloves.

## Control

Dogs that may hunt or have access to offal or carcasses of *Echinococcus* intermediate hosts within an endemic area should be treated at least every six weeks with an effective anthelmintic containing praziquantel or epsiprantel.

Dogs should not be fed undercooked or raw meat and care should be taken to prevent them having access to raw offal and carcasses.



Adapted from the original ESCCAP Guideline 01 Second Edition – September 2010 © ESCCAP 2010. All rights reserved.

ISBN 978-1-907259-41-8

ESCCAP guidelines are made possible by sponsorship from ALL the major leading pharmaceutical companies.

### Ruby Sponsors:



### Sapphire Sponsors:

ESCCAP Secretariat  
Malvern Hills Science Park  
Geraldine Road, Malvern  
WR14 3SZ  
United Kingdom

Tel: +44 (0) 1684 585135  
[www.esccap.org](http://www.esccap.org)

# 1 Modular Guide Series

## 1.6b: Fox tapeworm (*Echinococcus multilocularis*)

*Echinococcus multilocularis* (fox tapeworm) is a small cestode that inhabits the small intestine of dogs, foxes, some other canids and less commonly cats.

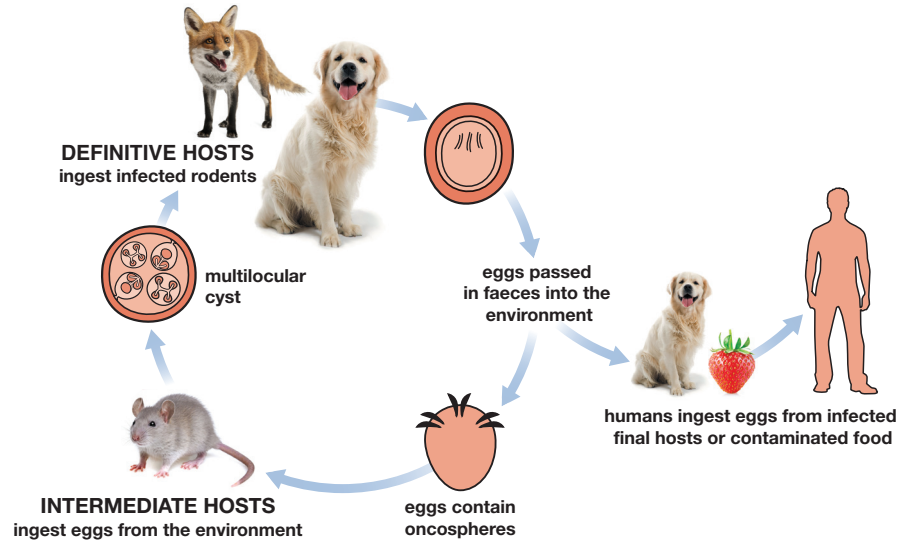
It is the cause of alveolar echinococcosis in humans, due to infection with eggs passed in the faeces by definitive hosts.

### Distribution

*Echinococcus multilocularis* is endemic in a wide area of central and eastern Europe.

### Life Cycle

Adult worms inhabit the small intestine of the final hosts with the terminal proglottid breaking off once it matures. This is passed in faeces and includes eggs containing the larval stages (oncospheres), which are immediately infective to an intermediate host, normally voles (arvicolidae). Within the intermediate host the immature tapeworm leaves the intestine, coming to rest in the liver where it develops into a multilocular cyst containing many immature tapeworms. Final hosts are infected when they ingest the cysts within the intermediate hosts.



## Clinical Signs

Infected dogs are very unlikely to show clinical signs. The segments are too small for them to be evident in faeces.

Although extremely rare, dogs may also act as intermediate hosts and show severe clinical signs.

## Diagnosis

Specific diagnosis of *Echinococcus* infections in definitive hosts is difficult as the taeniid eggs cannot be differentiated morphologically and are passed intermittently. Coproantigen tests are not available commercially and Polymerase Chain Reaction tests (PCRs) for species and/ or genotype identification are only performed in specialised laboratories. Therefore, in *Echinococcus* endemic areas taeniid infections based on egg detection should be considered as potential *Echinococcus* infection.

## Treatment

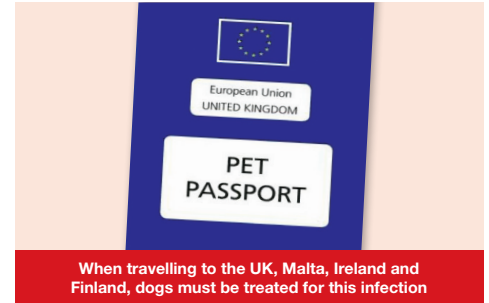Where animals are infected with *Echinococcus* species, treatment with an anthelmintic containing praziquantel or epsiprantel is advisable, carried out under veterinary supervision<sup>1</sup>.

Dogs should be shampooed to remove any parasite eggs adhering to the coat.

The faeces of treated dogs should be properly disposed of.

Personnel involved should use suitable protective clothing including protective gloves.

Cats, in contrast to dogs, are epidemiologically insignificant as sources of egg output as they are poor hosts for this worm. However, they do sporadically acquire infection and occasionally pass eggs, in contrast to dogs, where it is common to find eggs in the fur of infected animals. No eggs have been recovered to date from the coat of an infected cat. Since there is a small risk of cats carrying an infection, it is reasonable to recommend treatment in high-risk situations, for example prior to entry into countries where the infection is not present.



## Control

Dogs that may hunt and eat small prey should be treated at least every four weeks with an effective anthelmintic containing praziquantel or epsiprantel. Animals should not be fed undercooked or raw meat and care should be taken to prevent them hunting.

<sup>1</sup> See [www.esccap.org](http://www.esccap.org) for links to therapy tables by country or region.



Adapted from the original ESCCAP Guideline 01 Second Edition – September 2010 © ESCCAP 2010. All rights reserved.

ISBN 978-1-907259-41-8

ESCCAP guidelines are made possible by sponsorship from ALL the major leading pharmaceutical companies.

### Ruby Sponsors:



ESCCAP Secretariat  
Malvern Hills Science Park  
Geraldine Road, Malvern  
WR14 3SZ  
United Kingdom

Tel: +44 (0) 1684 585135  
[www.esccap.org](http://www.esccap.org)

# 1 Modular Guide Series

## 1.7: Flea tapeworm (*Dipylidium caninum*)

*Dipylidium caninum* is a tapeworm of dogs and cats.  
The flea or the chewing dog louse are intermediate hosts.

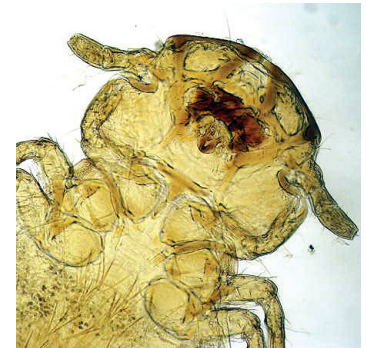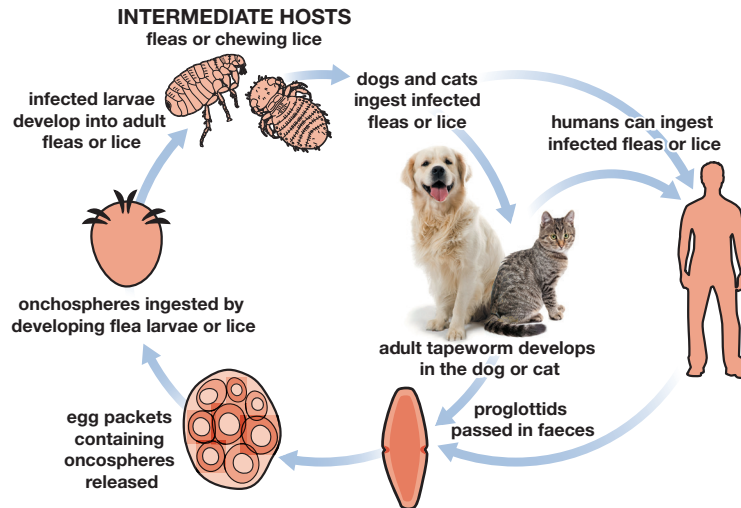
### Distribution

The parasite is common throughout Europe.

### Life Cycle

The intermediate hosts are the flea or the chewing dog louse and dogs and cats become infected when they ingest the infected insects. The adult tapeworm develops within the dog or cat in the small intestine. *Dipylidium caninum* is zoonotic and if humans ingest infected fleas or lice they can become infected, although this is rare.

The pre-patent period is approximately three weeks.



When chewing lice or fleas are ingested they can transmit *D. caninum*

## Clinical Signs

*Dipylidium caninum* is rarely associated with clinical signs in dogs or cats. There may be signs of anal pruritus.

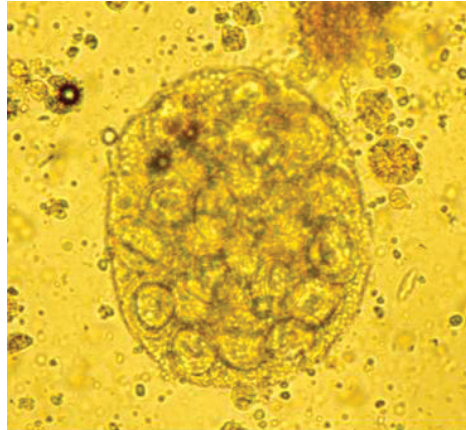
## Diagnosis

The white proglottids may be seen in fresh faeces or in the coat around the anus. When dry, these are shaped like pumpkin seeds and may be evident around the perianal area.

Sometimes proglottids may be seen leaving the anus of the animal and dry proglottids may be found in samples from the animal's bedding.

## Treatment

Treatment is by the administration of an effective anthelmintic at regular intervals<sup>1</sup>.



Egg packets containing oncospheres

## Control

*Dipylidium caninum* infection can be prevented by the effective control of fleas and lice.



Anal pruritus may be present

<sup>1</sup> See [www.esccap.org](http://www.esccap.org) for links to therapy tables by country or region.



Adapted from the original ESCCAP Guideline 01 Second Edition – September 2010 © ESCCAP 2010. All rights reserved.

ISBN 978-1-907259-41-8

ESCCAP guidelines are made possible by sponsorship from ALL the major leading pharmaceutical companies.

### Ruby Sponsors:



ESCCAP Secretariat  
Malvern Hills Science Park  
Geraldine Road, Malvern  
WR14 3SZ  
United Kingdom

Tel: +44 (0) 1684 585135  
[www.esccap.org](http://www.esccap.org)

# 1 Modular Guide Series

## 1.8: Taeniid tapeworms (*Taenia* spp.)

*Taenia* spp. are tapeworms that can infect dogs, cats and foxes by ingestion of intermediate hosts.

### Distribution

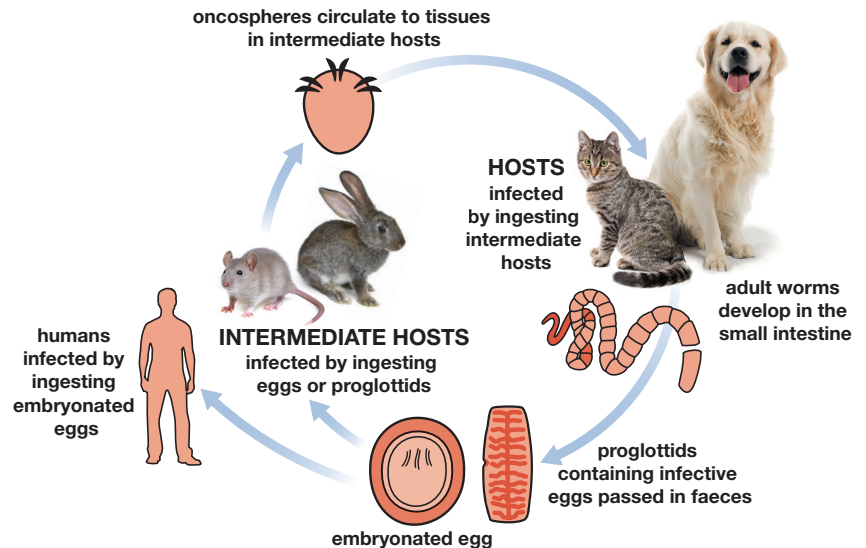
*Taenia* spp. are common throughout Europe.

### Life Cycle

The intermediate hosts are varied and, depending on the *Taenia* spp., range from sheep and cattle (*Taenia multiceps*) to rabbits (*Taenia serialis*, *Taenia pisiformis*), rodents (*Taenia taeniaeformis*), ruminants and pigs (*Taenia hydatigena*) and sheep and goats (*Taenia ovis*).

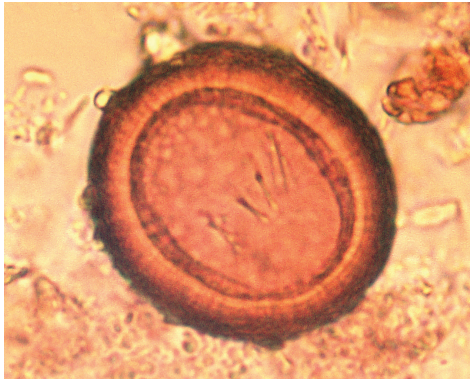
Dogs or cats are infected when they eat the tissues or viscera of infected hosts.

Adult worms can survive in the small intestine for several months up to several years.



## Clinical Signs

*Taenia* spp. are rarely associated with clinical signs, although the mature segments of the adult worm may result in anal irritation and cause the animal to rub its bottom along the ground. Owners may notice segments attached to the animal's coat after leaving the anus.



Taeniid egg

## Diagnosis

Taeniid eggs may be detected upon faecal examination and are usually seen singly, differentiating them from the egg packets of *Dipylidium caninum*.

Taeniid eggs cannot be differentiated microscopically from *Echinococcus* eggs. Therefore, in *Echinococcus* endemic areas taeniid infections based on egg detection should be considered as a potential *Echinococcus* infection.

Macroscopic examination of the faeces may demonstrate the presence of white proglottids, which are easily seen and unlike *D. caninum* each has only one genital pore.

## Treatment

Treatment is by the administration of an effective anthelmintic at suitable intervals which will most likely depend upon evidence of an existing infection<sup>1</sup>.

<sup>1</sup> See [www.esccap.org](http://www.esccap.org) for links to therapy tables by country or region.

## Control

Eggs can remain viable for lengthy periods in the environment. Owners should try and prevent dogs and cats having access to the various intermediate hosts.

The feeding of raw meat and viscera should be discouraged.



Hunting dogs and free roaming cats at higher risk of infection



Adapted from the original ESCCAP Guideline 01 Second Edition – September 2010 © ESCCAP 2010. All rights reserved.

ISBN 978-1-907259-41-8

ESCCAP guidelines are made possible by sponsorship from ALL the major leading pharmaceutical companies.

### Ruby Sponsors:



### Sapphire Sponsors:

ESCCAP Secretariat  
Malvern Hills Science Park  
Geraldine Road, Malvern  
WR14 3SZ  
United Kingdom

Tel: +44 (0) 1684 585135  
[www.esccap.org](http://www.esccap.org)

# 1 Modular Guide Series

## 1.9: Hookworms (*Ancylostoma* and *Uncinaria* spp.)

Hookworms are nematodes of the small intestine that can cause disease in dogs, cats and foxes.

Their common name is derived from their large mouthparts, which are set at an angle to the rest of the worm. All species feed by grasping and removing plugs of intestinal mucosa with their mouthparts thus damaging the mucosal surface. Infection is most common where animals have access to outdoor environments such as runs and kennels.

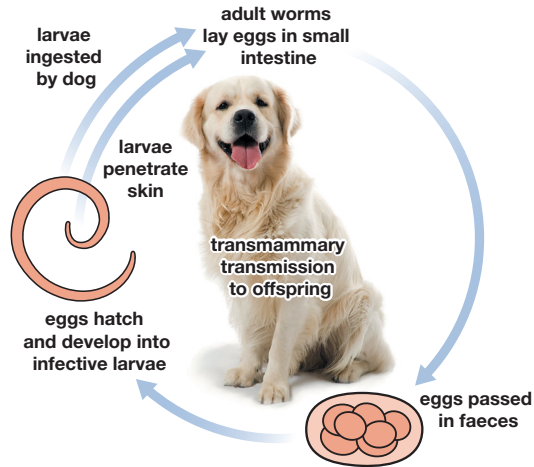
### Distribution

There are three significant species in Europe: *Ancylostoma caninum* (dogs), *Ancylostoma tubaeforme* (cats) and *Uncinaria stenocephala* (dogs and rarely cats). *Ancylostoma caninum* is found predominantly in central and southern Europe and *A. tubaeforme* is found throughout continental Europe. *Uncinaria stenocephala* is known as the northern hookworm as it tolerates colder climates and is found throughout Europe.

### Life Cycle

Adult worms inhabit the small intestine where they lay eggs that are then passed in the faeces.

The eggs hatch releasing larvae that develop to infective third stage larvae in the environment. These larvae are then ingested and develop into adult worms within 2–3 weeks.



Puppies can become infected while suckling



Hookworms are small nematodes that live in the intestine of infected dogs

Hookworms, most notably *Ancylostoma* spp. larvae, are also capable of penetrating the skin and making their way to the intestine. It is unlikely that this route of infection contributes greatly to the *U. stenocephala* life cycle.

Suckling pups can become infected with *A. caninum* by lactogenic transmission of larvae.

## Clinical Signs

Diarrhoea, weight loss and anaemia are the common clinical signs and in the case of *A. caninum* and *A. tubaeforme* the diarrhoea may contain blood.

Skin lesions can appear on the foot pads of dogs and cats caused by larvae burrowing into and along the skin.

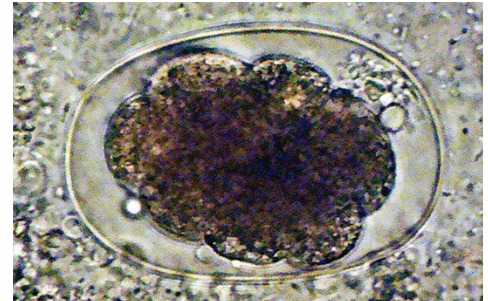
Transmission of *A. caninum* larvae through the milk can result in acute anaemia, which may prove fatal in young pups.

## Diagnosis

Diagnosis is based on identifying hookworm eggs in fresh or fixed faecal samples using a flotation method. Diagnosis in young puppies can be complicated by signs of disease occurring before infection is patent i.e. before eggs are passed in faeces.

## Treatment

Immunity does develop after exposure but is unlikely to be absolute, therefore animals in heavily infected environments may require regular anthelmintic therapy to control hookworm infections. Where young animals are clinically affected by the infection, supportive therapy may be necessary in addition to anthelmintic treatment<sup>1</sup>.



Infection can be diagnosed by faecal examination and identification of eggs

## Control

A sustained programme of treatment and management will need to be implemented for dogs and cats with access to a contaminated environment such as runs and kennels. This may necessitate treatment and where possible, removal of animals to a clean environment whilst the area is decontaminated.

<sup>1</sup> See [www.esccap.org](http://www.esccap.org) for links to therapy tables by country or region.



Adapted from the original ESCCAP Guideline 01 Second Edition – September 2010 © ESCCAP 2010. All rights reserved.

ISBN 978-1-907259-41-8

ESCCAP guidelines are made possible by sponsorship from ALL the major leading pharmaceutical companies.

### Ruby Sponsors:



### Sapphire Sponsors:

ESCCAP Secretariat  
Malvern Hills Science Park  
Geraldine Road, Malvern  
WR14 3SZ  
United Kingdom

Tel: +44 (0) 1684 585135  
[www.esccap.org](http://www.esccap.org)